



Technical challenges of lymphadenectomy in renal carcinoma performed with a 3D laparoscopic approach at a low pressure pneumoperitoneum due to associated pulmonary pathology – case report

Cristina E. Bujoreanu¹, Yarden Dor², Bogdan Petrut^{1,2,3}

1) Urology Department, "Prof. Dr. I. Chiricuta" Institute of Oncology, Cluj-Napoca, Romania

2) Urology Department, Iuliu Hatieganu University of Medicine and Pharmacy, Cluj-Napoca, Romania

3) ESUT - EAU Section of Uro-Technology, Training Group

Abstract

We report the case of a 63-year-old male patient presenting left renal cell carcinoma (75/70/60 mm) associated with retroperitoneal lymph node masses (peri hilar of 15 mm; lombo-aortic of 50/40/30 mm), known also with chronic obstructive pulmonary disease GOLD4, sleep apnea and asthma with oxygen-dependent chronic obstructive respiratory insufficiency, a BMI of 37 with grade III obesity. Surgical treatment was performed using a 3D transperitoneal laparoscopic approach. The surgery lasted 131 minutes, with 400 ml blood loss and grade 1 Clavien-Dindo post operative complications. An optimal pulmonary ventilation of the patient during surgery required a low intra-abdominal pressure (10 mmHg) which raised technical difficulties due to the lymph node mass dissection from the great vessels in a small operative field on an already obese patient with a voluminous renal tumor. The 3D transperitoneal laparoscopic approach was feasible within safe oncologic parameters.

Keywords: renal cell carcinoma, 3D laparoscopy, pneumoperitoneum, lymphadenectomy

Introduction

Renal cell carcinoma (RCC) is one of the ten most common cancers worldwide, affecting men twice more than females, especially in the age group of 60-70 years. In case of surgical treatment being indicated - partial or radical nephrectomy [1], loco-regional lymphadenectomy is performed in case of imaging or intra-operative suspicion of lymph node tumoral involvement [2]. The minimal invasive approach can bring challenging technical implications, but shortens the recovery time of the patient with less blood loss compared to open surgery [3]. The regular pneumoperitoneum for the laparoscopic approach is 12-15 mmHg. When pulmonary pathology is added (e.g. chronic obstructive pulmonary disease COPD), a lower pressure is imposed to avoid conversion to open surgery

if pulmonary ventilation is endangered [4,5,6]. The lower intra-abdominal pressure requires adaptations of the surgical management, since the operative field is reduced, with less control of possible hemorrhagic events [7].

Case report

Disease diagnosis

A 63 years old patient presented to our department with an episode of macroscopic hematuria, ultrasound examination showing a left renal tumor further confirmed by computer tomography (CT- Thorax/Abdomen/Pelvis). Blood and urine analyses along with spirometry were performed during hospital admission*).

Patient history

- *pulmonary*: GOLD4 stage CPOD, sleep apnea and asthma with oxygen-dependent chronic obstructive respiratory

DOI: 10.15386/mpr-2055

Manuscript received: 28.01.2021

Received in revised form: 16.11.2021

Accepted: 05.12.2021

Address for correspondence:
yardendo1@gmail.com

This work is licensed under a Creative Commons Attribution-NonCommercial-NoDerivatives 4.0 International License

insufficiency, ex-smoker (3 packs/year) until 7 years ago.

- *cardiac*: arterial hypertension stage III, mixt cardiopathy (ischemic and hypertensive), degenerative aortic disease with aortic insufficiency grade II, moderate tricuspid insufficiency and right bundle branch block.

- *psychiatric*: mild depression

- *surgical history*: appendectomy and volvulus surgical treatment (1982).

* The CT scan (Thorax/Abdomen/Pelvis) revealed a left renal tumor (75/70/60 mm) with renal pelvis involvement on the anterior hemivalve, associating retroperitoneal lymph node masses (peri hilar of 15 mm; latero-aortic of 50/40/30 mm). The left kidney measured 250/170/60 mm. A small exophytic simple cyst (12 mm) was also found on the inferior renal pole, closely related to the caudal lombo-aortic lymphadenopathy (Figure 1). No suspicion of pulmonary or bone metastases were reported.

Therapeutic strategy

Radical nephrectomy and retroperitoneal lymphadenectomy using a transperitoneal 3D laparoscopic approach, with the risk of conversion to an open surgery

being imposed in case of complications related to pulmonary ventilation. The case was ASA III.

Surgical steps

Three trocars were placed respecting the triangulation principle with the patient in lateral decubitus (12 mmHg pneumoperitoneum). This is the standard number of trocars for laparoscopic radical nephrectomy performed in our center. The patient presented a high BMI, so trocar placement was challenging due to unreliable landmarks (umbilicus), thickness of the abdominal wall and body habitus. The xiphoid process with hip/ribs were used as landmarks. The descending colon was mobilized medially (Kocher maneuver), accessing retroperitoneal space, using a fenestrated grasper and LigaSure™ bipolar device (Figure 2A). The intra-abdominal pressure needed to be decreased (10 mmHg) for the anesthesiology team to properly ventilate the patient and remained so until the end. The left ureter was identified, the cranial dissection reached the renal pedicle, by excising the first latero-aortic lymph node mass, situated caudal to the left renal pedicle (Figure 2B). The excised lymph node mass was placed in an Endo Bag™.

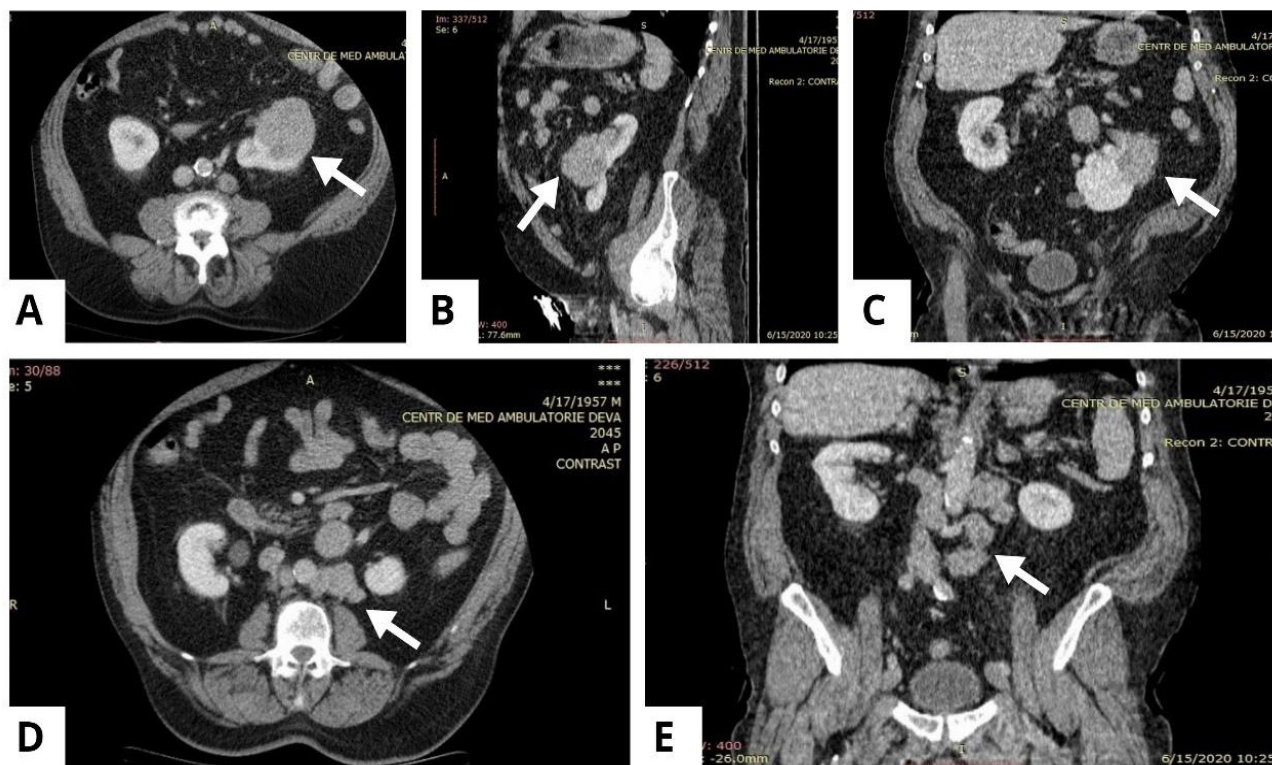


Figure 1. Contrast enhanced abdominopelvic CT scan: left renal tumoral mass on (A) axial section; (B) sagittal section; (C) coronal section. Lymph node masses in the vicinity of the renal pedicle and latero-aortic on (D) axial section; (E) coronal section.

*Spirometry under Brimica 340/12 mcg: FVC: 2.46L/62%, FEV1: 1.55L/50%, PVPI: 64%, SpO2: 84%.

*Laboratory examinations showed values within normal range: Hemoglobin level (15.9 g/dl), Neutrophilia (5280/ μ L), platelet level (176000/ μ L), Ca (9.2 mg/dl), K (3.81 mmol/L), Na (142 mmol/L), LDH (275U/L), creatinine (1.02 mg/dl), urea (41.2 mg/dl). Urine analysis presented no pathological findings except hematuria and urine culture was negative. Karnofsky Performance status 80 points, ECOG 1.

The dissection of the pedicle imposed difficulty in reaching the renal artery situated posterior to the renal vein, therefore the renal vein was clipped (Hem-o-lok® clips) and sectioned first. There were numerous collateral vessels adjacent to the lymphatic mass (Figure 2C,D). Adrenalectomy was performed as the renal artery was identified, clipped and sectioned. (Figure 2E). The tumoral kidney was voluminous and the operative field small, so the surgery continued with the lumbar lymphadenectomy as the dissection of the kidney from surrounding tissues would mobilize the kidney in the dissection area. The tumoral lymph node masses and the tumoral kidney presented numerous collateral vessels. The 10 mmHg pneumoperitoneum was not able to help compress the

veins (hemostasis) and lower blood loss with the usage of aspirator lowering visibility, prolonging the surgery. The simple renal cystic mass (inferior pole of the kidney) suggested the position of the lymph node mass. This latero-aortic mass was excised in its integrity with the dissection being performed cranial to caudal, medial to lateral (Figure 2F, G) and placed in the nearby Endo Bag™. With attentive hemostasis, the surgery continued by dissecting the kidney from adjacent tissues, caudo-cranial and medio-lateral. The voluminous tumoral kidney with the lymphatic masses were exteriorized in the Endo Bag™ and sent to histopathology. A hemostatic mesh (fibrin) was placed on the psoas muscle, intra-abdominal gas was evacuated, one retroperitoneal drainage tube was placed and entry points were sutured.

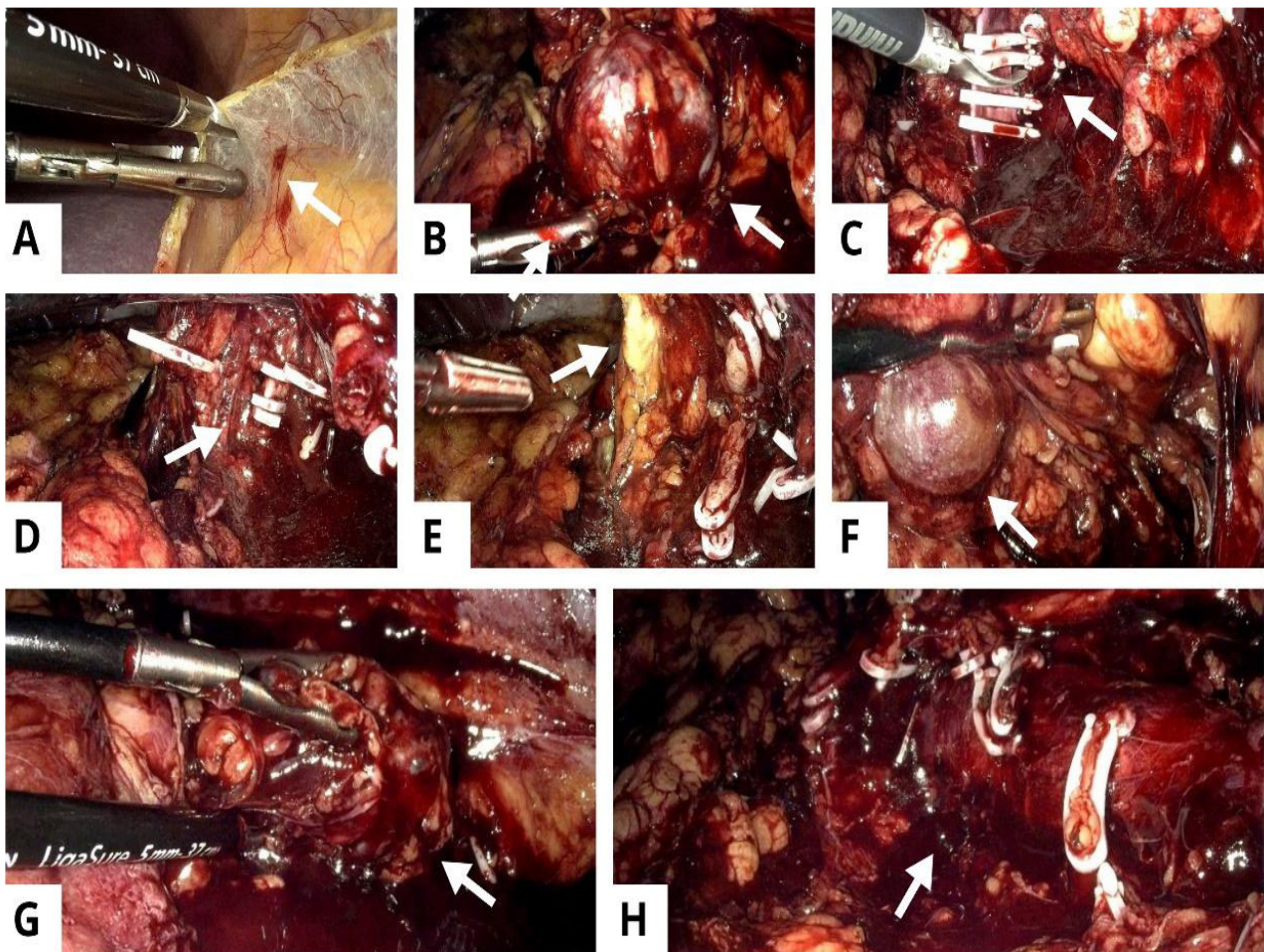


Figure 2. Intra operative steps: (A) mobilizing the descending colon accessing the retroperitoneal space; (B) dissecting the first lymph node mass- caudal from the renal pedicle; (C) clamping and cutting the renal vein (D) and the renal artery (see arrow); (E) excising the suprarenal gland (see arrow); (F) renal cyst; (G) excising latero-aortic lymph node mass; (H) final aspect with all lymph nodes removed, the aorta with clips along the location of previously renal pedicle and pedicles of lymph node masses.

Results

Results are presented in table I - T3aN1M0R0L1V1 papillary left renal carcinoma. The patient currently undergoes oncologic and endocrinologic follow up, with imaging evaluation being performed every 6 months (CT/

MRI). No adjuvant treatment was applied up to the latest follow-up (10 months after operation) as there was no imaging suspicion of disease recurrence or metastases. The renal function maintained within normal range.

Table I. Peri and post operative results.

Operative time (minutes)	131
• radical nephrectomy	97
• lymphadenectomy	34
Blood loss (ml)	400
Drainage suppression (day after surgery)	2
Patient discharged (day after surgery)	3
Histopathology report	papillary type 2 left renal carcinoma, ISUP grade 3, with metastasis in all the excised lymph nodes (cumulated a mass of 80/75/32 mm) and non-tumoral left adrenal gland
• immunohistochemistry profile	CK7, AMACR, CD10, PAX8 and EMA positive with a 255 ki67 proliferation index.
• staging	pT3a N1 M0 R0 L1 V1 (M status from clinical/imaging/ intra operative data)
Clavien-Dindo complication grade (30 days post operative)	I *Anesthesia and post operative Intensive care unit (ICU): Post operative the patient received antiemetics, antipyretics, prokinetic agents, analgesics, electrolytes, prophylactic antibiotics and anticoagulants (low-molecular-weight heparin: venous thrombosis prophylaxis started 24 hours after surgery for the hospitalization period), bronchodilators and physiotherapy. The patient received CPAP (Continuous positive airway pressure during ICU stay (2.5 L/min).

Discussion and conclusion

Habitual volume of pneumoperitoneum may induce hypercapnia and acidosis due to rapid CO₂ absorption into the blood circulation, also lung atelectasis which will prompt peri operative pulmonary dysfunction (mechanical stress) due to the cyclic recruitment of atelectasis areas [5,7]. Due to effective monitoring of pulmonary ventilation during surgery, the patients present manageable risks of pulmonary events due to pneumoperitoneum, with conversion being performed in due time if imposed. A study comparing low (8 mmHg) versus high (12 mmHg) pressure pneumoperitoneum in laparoscopic cholecystectomy in two groups of patients, reported no difference in the surgical duration or intra / post operative complications, even though it perceived difficulties from a technical point of view to work with low pressure pneumoperitoneum. The low-pressure pneumoperitoneum group presented significantly better intraoperative pO₂ levels, less post operative pain, reduced analgesics requirements and shorter hospital stay [8]. To avoid conversion and allow an optimal pulmonary ventilation for our patient, the positive end-expiratory pressure (PEEP) was raised and recruitment maneuvers were applied to re-expand collapsed air spaces, with a 10 mmHg pneumoperitoneum being imposed, to benefit the post operative advantages of laparoscopy such as a fast recovery with reduced complications and required

pain medication. This approach within the presence of grade III obesity imposed technical difficulties. The intra operative field was reduced, not favoring the hemostasis of collateral veins. The elements of the renal pedicle were difficult to dissect, due to the caudal lymph node mass which also presented rich arterial supply. To assure the lymph node mass dissection within oncologic safety, the renal vein had to be clipped and cut before the artery, so the kidney was full with blood during its dissection. Furthermore, the latero-aortic lymph node mass was removed with only the renal pedicle being dissected (the radical nephrectomy was not completed), to not limit even more the operative field with a movable voluminous renal mass. Both lymph node masses implied high risk of hemorrhagic events and experience to manage them if required. Lymphadenectomy is not routinely indicated to accompany radical nephrectomy unless involvement is visible on imaging or intra-operative, since studies have shown that it does not increase survival [9,10]. Lymph node dissection does improve staging and it is not associated with increased risk of peri operative morbidity in centers with experience. There is no established template for lymph node dissection as studies have shown that 35% of cases present with sentinel lymphatic drainage outside the loco-regional retroperitoneal template [11]. In this case, the lymphadenectomy was imposed due to imaging diagnosis.

Studies showed that ipsilateral adrenalectomy does not improve prognosis or surgical outcomes if routinely performed [12]. In our case, ipsilateral adrenalectomy was imposed to assure an optimal dissection of the renal tumor within optimal oncologic surgical margins. The imaging follow-up is recommended to be performed every 6 months – CT scan (Thorax/ Abdomen/ Pelvis). In case of imaging suspicion of disease recurrence or metastasis, the patient will undergo oncologic treatment as recommended by a tumor board, including the option of surgical management if applied. The 3D laparoscopic approach for voluminous renal tumors with lymph node involvement is feasible, even if technically challenging due to limited pneumoperitoneum imposed by associated pulmonary pathology and a high BMI. It also offered the advantages of early post operative ambulation and reduced pain warranting less analgesics usage with minimal post operative ileus. Referral of these cases is recommended for experienced laparoscopic surgical teams working in high volume centers to assure optimal control of possible hemorrhagic events and on time conversion to open surgery if required.

References

1. Hsieh JJ, Purdue MP, Signoretti S, Swanton C, Albiges L, Schmidinger M, et al. Renal cell carcinoma. *Nat Rev Dis Prim.* 2017;3:17009.
2. Blom JH, van Poppel H, Maréchal JM, Jacqmin D, Schröder FH, de Pijck L, et al. Radical nephrectomy with and without lymph-node dissection: final results of European Organization for Research and Treatment of Cancer (EORTC) randomized phase 3 trial 30881. *Eur Urol.* 2009;55:28–34.
3. Wang D, Xiao Z, Shou J, Li C, Xing N. Comparison of laparoscopy and open radical nephrectomy of renal cell cancer. *Open Med (Wars).* 2019;14:392–397.
4. Lumb A, Biercamp C. Chronic obstructive pulmonary disease and anaesthesia. *Contin Educ Anaesthesia Crit Care Pain.* 2014;14:1–5.
5. Falcão LFDR, Battisti FPL, Oliveira Júnior IS, Ferez D. Pulmonary function alteration in laparoscopic surgery with pneumoperitoneum and abdominal wall elevation. *Braz J Anesthesiol.* 2018;68:215–216.
6. Loring SH, Behazin N, Novero A, Novack V, Jones SB, O'Donnell CR, et al. Respiratory mechanical effects of surgical pneumoperitoneum in humans. *J Appl Physiol* (1985). 2014;117:1074–1079.
7. Gutt CN, Oniu T, Mehrabi A, Schemmer P, Kashfi A, Kraus T, et al. Circulatory and respiratory complications of carbon dioxide insufflation. *Dig Surg.* 2004;21:95–105.
8. Joshipura VP, Haribhakti SP, Patel NR, Naik RP, Soni HN, Patel B, et al. A prospective randomized, controlled study comparing low pressure versus high pressure pneumoperitoneum during laparoscopic cholecystectomy. *Surg Laparosc Endosc Percutan Tech.* 2009;19:234–240. Available from: <http://ovidsp.ovid.com/ovidweb.cgi?T=JS&PAGE=reference&D=emed9&NEWS=N&AN=2009424075>
9. Jung US, Choi JS, Bae J, Lee WM, Eom JM. Systemic laparoscopic para-aortic lymphadenectomy to the left renal vein. *JSLs.* 2019;23:e2018.00110.
10. Freedland SJ, Dekernion JB. Role of lymphadenectomy for patients undergoing radical nephrectomy for renal cell carcinoma. *Rev Urol.* 2003;5:191–195.
11. Unadkat P, Olumi AF, Gershman B. The Role of Lymphadenectomy in Patients with Advanced Renal Cell Carcinoma. *Urol Clin North Am.* 2020;47:371–377.
12. Weight CJ, Mulders PF, Pantuck AJ, Thompson RH. The Role of Adrenalectomy in Renal Cancer. *Eur Urol Focus.* 2016;1:251–257.